


後七位  
新井春次郎  
講義

高橋・米川両学士講  
解剖学

卷之四



[從七位新井春次郎講義]解剖学 卷之四 高橋・米川両学士講

内麻葉目次

終端

洞紀田

口腔

(一) 口腔の構造及び口唇の運動


(二) 舌

回舌

四口蓋

咽喉

會食





内臓學

*Splanchnologia (Eingeweidelehre)*

内臓 *Viscera* : 脊柱之前ニ位セル体腔ニ内臓腔ト称スル腔洞中ニ在ル臓器ヲ總稱スルニシテ生活ト生殖トノ機能ヲ担フニテリ且機能ニ依リ四至系ニ類別ス

第一 消化器系統 *Organs digestivis (Verdauungsorgane)*

第二 呼吸器系統 *Organa respirativa (athmungsorgane)*

第三 泌尿器系統 *Organa urinaria (Harnorgane)*

第四 生殖器系統 *Organa genitalis (Geschlechtsapparat)*

内臓腔 : 口腔、胸腔、腹腔、骨髄腔、骨髄腔ニシテハ胸腔、肋骨間腔、

脊椎一部ニ圍繞スル其上界ハ第七頸椎、下界ハ第一腰椎、

端ニ成ルニシテ、胸廓トシテ *Spaculum Thoracis superioris*

又下界ハ肋骨間腔ニシテ、肋骨間腔トシテ *Spaculum Thoracis inferioris* 上ニシテ、肋骨間腔トシテ

ニシテ胸廓、下口 *Spaculum Thoracis inferioris* 上ニシテ、肋骨間腔トシテ

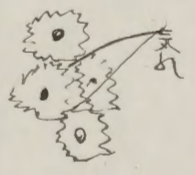
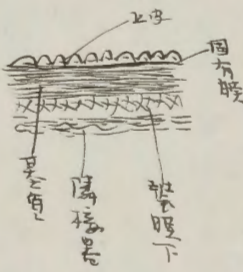
解剖学

之之即内腔腔中内腔より外腔へ骨盤腔と互に交通シタル内腔より  
全形に卵形にシテ其上部より部より上より向に横隔膜より膜より狭小部より  
向に尾端骨上軸骨隆起より其上部より其下部より軟骨より成り内腔腔の口  
腔の頸部より内腔腔の外に内腔腔の頸部より成り内腔腔の頸部より成り  
内腔腔の頸部より成り内腔腔の頸部より成り内腔腔の頸部より成り  
*Foramen* とも呼ばる。内腔腔の頸部より成り内腔腔の頸部より成り  
内腔腔の頸部より成り内腔腔の頸部より成り内腔腔の頸部より成り  
内腔腔の頸部より成り内腔腔の頸部より成り内腔腔の頸部より成り  
内腔腔の頸部より成り内腔腔の頸部より成り内腔腔の頸部より成り

護液腔 *Membrana Serosa*  
此膜は多量の液体を貯蔵し、その一部は消化の補助に用いられる。内腔腔  
及び腔室中、山相入りとなり、而して且つ消化の補助に用いられる。内腔腔  
ニテラハリ、内腔腔の頸部より成り内腔腔の頸部より成り内腔腔の頸部より成り  
外腔腔の頸部より成り内腔腔の頸部より成り内腔腔の頸部より成り  
内腔腔の頸部より成り内腔腔の頸部より成り内腔腔の頸部より成り  
内腔腔の頸部より成り内腔腔の頸部より成り内腔腔の頸部より成り  
内腔腔の頸部より成り内腔腔の頸部より成り内腔腔の頸部より成り  
内腔腔の頸部より成り内腔腔の頸部より成り内腔腔の頸部より成り

### 漿膜の構造

漿膜は多量の液体を貯蔵し、その一部は消化の補助に用いられる。内腔腔  
及び腔室中、山相入りとなり、而して且つ消化の補助に用いられる。内腔腔  
ニテラハリ、内腔腔の頸部より成り内腔腔の頸部より成り内腔腔の頸部より成り  
外腔腔の頸部より成り内腔腔の頸部より成り内腔腔の頸部より成り  
内腔腔の頸部より成り内腔腔の頸部より成り内腔腔の頸部より成り  
内腔腔の頸部より成り内腔腔の頸部より成り内腔腔の頸部より成り  
内腔腔の頸部より成り内腔腔の頸部より成り内腔腔の頸部より成り  
内腔腔の頸部より成り内腔腔の頸部より成り内腔腔の頸部より成り



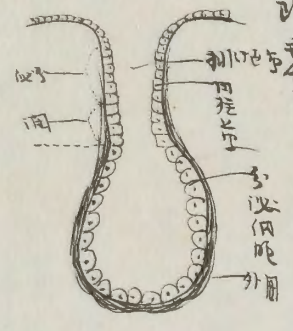
漿膜は多量の液体を貯蔵し、その一部は消化の補助に用いられる。内腔腔  
及び腔室中、山相入りとなり、而して且つ消化の補助に用いられる。内腔腔  
ニテラハリ、内腔腔の頸部より成り内腔腔の頸部より成り内腔腔の頸部より成り  
外腔腔の頸部より成り内腔腔の頸部より成り内腔腔の頸部より成り  
内腔腔の頸部より成り内腔腔の頸部より成り内腔腔の頸部より成り  
内腔腔の頸部より成り内腔腔の頸部より成り内腔腔の頸部より成り  
内腔腔の頸部より成り内腔腔の頸部より成り内腔腔の頸部より成り  
内腔腔の頸部より成り内腔腔の頸部より成り内腔腔の頸部より成り

### 粘液膜

粘液膜は消化管の内壁を覆い、消化物を滑らかにし、消化を促進する。内腔腔  
及び腔室中、山相入りとなり、而して且つ消化の補助に用いられる。内腔腔  
ニテラハリ、内腔腔の頸部より成り内腔腔の頸部より成り内腔腔の頸部より成り  
外腔腔の頸部より成り内腔腔の頸部より成り内腔腔の頸部より成り  
内腔腔の頸部より成り内腔腔の頸部より成り内腔腔の頸部より成り  
内腔腔の頸部より成り内腔腔の頸部より成り内腔腔の頸部より成り  
内腔腔の頸部より成り内腔腔の頸部より成り内腔腔の頸部より成り  
内腔腔の頸部より成り内腔腔の頸部より成り内腔腔の頸部より成り



其の長短は偏るは先腺に於て大差あり故に腺種類を以て於ては第一排泄  
 管の多きより少きを以て管の多きより少きを以て管の多きより少きを以て管の多  
 其の長短は偏るは先腺に於て大差あり故に腺種類を以て於ては第一排泄  
 管の多きより少きを以て管の多きより少きを以て管の多きより少きを以て管の多



其の長短は偏るは先腺に於て大差あり故に腺種類を以て於ては第一排泄  
 管の多きより少きを以て管の多きより少きを以て管の多きより少きを以て管の多  
 其の長短は偏るは先腺に於て大差あり故に腺種類を以て於ては第一排泄  
 管の多きより少きを以て管の多きより少きを以て管の多きより少きを以て管の多

其の長短は偏るは先腺に於て大差あり故に腺種類を以て於ては第一排泄  
 管の多きより少きを以て管の多きより少きを以て管の多きより少きを以て管の多

消化器

*Pezomachus (Pezomachus)*

消化器は口腔より肛門に至る所を腸管とし外体より食物を取り之を咀嚼  
消化して之を吸収再消化作用を類化作用 *Assimilation*  
シテ之を已に營養物質として働かし又其の大部分を老廢物として其  
便 *Faeces* として排出せしむる可なり故に之を消化器管とす  
之の消化器管 *Canalis alimentarius* 長さ平均十メートルに達  
常体長五分の一倍あり且消化器管の最も細く且腸部、胸腔に  
位し下部は腸腔の胃腔に在り且壁の筋腔の筋織膜の外  
層有(心臓)三部あり其の腸腔は上下して消化器管の外面に覆  
はれ而して横隔膜の上部にあり口腔、咽喉、食管、胃、腸、下部に在り  
胃は腸より而して肝臓、脾臓、腸管中開口に腺

口腔 *Mundhöhle* *Oesophagus*

消化器の初端は口腔下部に位し上下の両側の間位に此に於て食物は咀嚼  
嚥して之を唾液と混和し食塊 *Bissen* として食道に送り之を消化器管に送り  
之を消化し腸腔に送り之を腸腔に送り之を腸腔に送り之を腸腔に送り之を腸腔に送り



骨より先骨へ連る筋あり。舌のコン境より上部より舌骨、口蓋、ヨウ境より前方  
咽峽、舌境より口腔ヲ閉鎖スル所、舌状並列スル所、歯牙、依テ前部ノ  
二腔ニ別レ其ノ前部ニシテ、ヨウ境ニシテ

前庭口腔 *Vestibulum Oris* 唇ノ内ニシテ、*Palatum*  
固方口腔 *Caelum Oris* *Eigentliche Mundhöhle*  
一舌真口腔

ト其ノ之、両腔ニ出牙ヲ閉スル所、骨状、白止歯、下顎骨格、前縁ト、間ニ生ル  
間隙、依テ斗リ交通スルナリ、而シテ出牙ヲ閉スル所、而シテ交通スルナリ、トナリ  
腔トナリ、而シテ

前庭口腔ニ前部、口蓋、  
固方口腔ニ前部、歯蓋、舌根、舌部、頰、舌部、歯蓋、舌根、舌部、頰、舌部、  
舌蓋、舌部、口蓋、下部、舌部、舌蓋、舌部、舌蓋、舌部、舌蓋、舌部、  
口蓋、頰 *Labia et Buccae* (*Superior Buccae*)  
口蓋、上下二個、辨状、肉片、舌部、舌部、舌部、舌部、舌部、舌部、  
*Superior* 上部、下部、舌部、舌部、舌部、舌部、舌部、舌部、  
舌部、舌部、舌部、舌部、舌部、舌部、舌部、舌部、舌部、舌部、

口蓋、上下二個、辨状、肉片、舌部、舌部、舌部、舌部、舌部、舌部、  
*Superior* 上部、下部、舌部、舌部、舌部、舌部、舌部、舌部、  
舌部、舌部、舌部、舌部、舌部、舌部、舌部、舌部、舌部、舌部、

*Oris* ニシテ、前部、合ニ、口角、舌口、舌連合トナリ、上唇、外面、中実、

筋、鼻中隔、  
*Philtrum* = *Sulcus nasolabialis* 鼻、舌、溝、  
*Philtrum* = *Sulcus nasolabialis* 鼻、舌、溝、

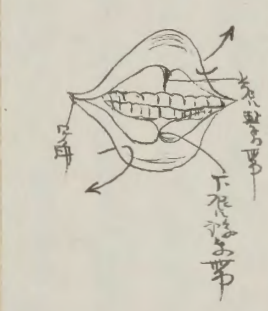

外下角、斜メ、口角、向テ、舌、  
*Cus nasolabialis lateralis* 鼻、舌、溝、  
*Cus nasolabialis lateralis* 鼻、舌、溝、

後、並行、  
*Chilum mentis labialis* 唇、  
*Chilum mentis labialis* 唇、

顔面外子、一系統、  
舌、毛、生、  
舌、毛、生、

舌、毛、生、  
舌、毛、生、  
舌、毛、生、

舌、毛、生、  
舌、毛、生、  
舌、毛、生、



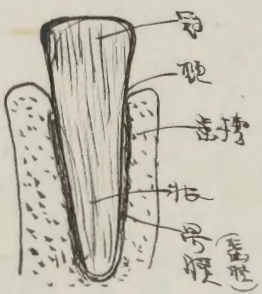






上齒牙

上齒牙: 前歯の総称。上下の歯。歯槽の中にある。根の長さは  
 約 1.5cm。根の太さは約 0.5cm。根の先端は歯肉に埋まるとして、  
 露出している部分は歯冠である。根の内部には歯髄管があり、  
 歯髄が流れている。歯冠の表面はエナメル質で覆われており、  
 非常に硬い。歯冠の内部には歯質があり、歯髄管が通っている。  
 歯冠の基部は歯頸である。歯頸は歯冠と歯根の境界線に  
 あり、歯肉が着いており、歯垢が溜まりやすいため、歯  
 周炎の原因となる。歯根は顎骨に埋まっており、根の内部  
 には歯髄管が通っていない。歯根の表面は象牙質で覆われて  
 いる。



歯髄管の入り口は歯冠の基部にある。歯髄管の内部には歯髄が  
 流れている。歯髄管の外部には歯髄鞘があり、歯髄を保護する。  
 歯髄鞘の内部には歯髄液があり、歯髄を栄養する。歯髄液の  
 循環は歯髄の健康に重要な役割を果たしている。歯髄管の閉塞  
 は歯髄の壊死を招き、歯痛の原因となる。歯髄管の閉塞を防ぐ  
 ためには、歯の腐蝕を防ぐことが重要である。

水之歯 (之切歯)

Bleibende Zähne 永久歯、乳歯に代わって生え続ける歯。

$$\begin{array}{r}
 2-1 \quad 4 \quad 1 \quad \times \\
 \hline
 2-1 \quad 4 \quad 2 \quad 2 = 10 \quad \rightarrow 20
 \end{array}$$

永久歯の数は、上下両側、歯肉の内側に、それぞれ 8 本ずつ、  
 合計 28 本。

乳歯	8	8	1	4	1	2	2	2	2	16
永久歯	8	8	1	2	1	2	2	1	2	20

子歯の歯根は、乳歯の歯根より短く、歯肉の中に埋まっている。乳歯の歯根は、歯肉から長く突き出ている。

門歯 (切歯) Dentens incisivi (Schneidezähne)

門歯は上下各四個あり、合計八個ある。歯肉の突出部は、  
 鋭く、鋭利な切歯である。門歯は、食物を切断する役割を  
 果たしている。門歯の歯根は、歯肉の中に埋まっている。門  
 歯の歯冠は、歯肉の突出部から突き出ている。門歯の歯根は、  
 歯肉の中に埋まっている。門歯の歯冠は、歯肉の突出部から  
 突き出ている。門歯の歯根は、歯肉の中に埋まっている。門  
 歯の歯冠は、歯肉の突出部から突き出ている。

犬歯 Canini (Canines (Schneidezähne))

犬歯は上下各二個あり、合計四個ある。歯肉の突出部は、  
 鋭く、鋭利な切歯である。犬歯は、食物を切断する役割を  
 果たしている。犬歯の歯根は、歯肉の中に埋まっている。犬  
 歯の歯冠は、歯肉の突出部から突き出ている。犬歯の歯根は、  
 歯肉の中に埋まっている。犬歯の歯冠は、歯肉の突出部から  
 突き出ている。犬歯の歯根は、歯肉の中に埋まっている。犬  
 歯の歯冠は、歯肉の突出部から突き出ている。

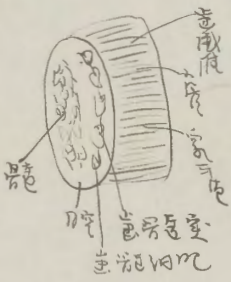








丹生ノ前成スルヲワルガクニシテモ此ノ内胞ヲ造出細胞  
 Abzithlastenニ號シテ内胞ニシテモ其ノ行ハナクモ其ノ行ハ  
 其ノ中ノ一部ヲ造出 Zahnfaserニシテ其ノ行ハ  
 其ノ内胞ニシテモ其ノ行ハナクモ其ノ行ハナクモ其ノ行ハ



### 造出細胞 Entwi ckelung der Zahnne

造出細胞ニシテモ其ノ行ハナクモ其ノ行ハナクモ其ノ行ハ  
 七ノ月ニ成リタルノ其ノ行ハナクモ其ノ行ハナクモ其ノ行ハ  
 造出細胞ニシテモ其ノ行ハナクモ其ノ行ハナクモ其ノ行ハ  
 造出細胞ニシテモ其ノ行ハナクモ其ノ行ハナクモ其ノ行ハ  
 造出細胞ニシテモ其ノ行ハナクモ其ノ行ハナクモ其ノ行ハ

中ニシテモ其ノ行ハナクモ其ノ行ハナクモ其ノ行ハ

造出細胞ニシテモ其ノ行ハナクモ其ノ行ハナクモ其ノ行ハ

造出細胞ニシテモ其ノ行ハナクモ其ノ行ハナクモ其ノ行ハ

造出細胞ニシテモ其ノ行ハナクモ其ノ行ハナクモ其ノ行ハ

造出細胞ニシテモ其ノ行ハナクモ其ノ行ハナクモ其ノ行ハ

造出細胞ニシテモ其ノ行ハナクモ其ノ行ハナクモ其ノ行ハ

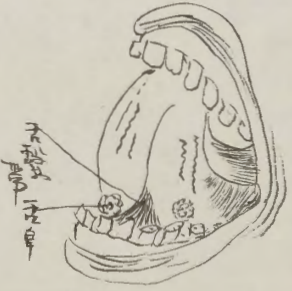
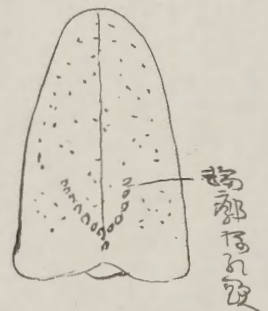
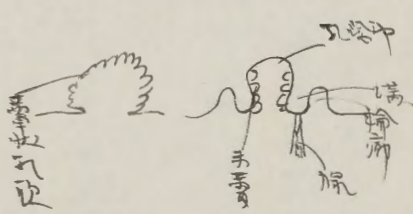


造出細胞ニシテモ其ノ行ハナクモ其ノ行ハナクモ其ノ行ハ

造出細胞ニシテモ其ノ行ハナクモ其ノ行ハナクモ其ノ行ハ

造出細胞ニシテモ其ノ行ハナクモ其ノ行ハナクモ其ノ行ハ



三、三、三



白草狀乳歯

之、四種中、且大、中、小、大、之、条、状、乳、歯、同、在、之、殊、之、于、空、舌、及、舌、上、其、形、一、痛、同、之、而、舌、上、有、之、且、遊、離、端、許、多、之、乳、歯、有、之、殊、之、ト、其、本、其、成、リ、且、且、血、管、之、管、内、リ、以、テ、布、兜、ナ、リ、ト、マ、

白葉狀乳歯

之、二、于、指、之、及、保、之、撥、動、發、成、之、並、列、之、多、ク、味、骨、有、之、味、感、覺、ナ、リ、主、サ、ト、ハ、手、動、之、ト、之、殊、之、突、之、ト、著、明、ナ、リ、

白輪形乳歯

之、二、最、大、之、乳、歯、之、其、形、ハ、ハ、モ、十、五、ノ、者、之、于、舌、根、于、以、此、ノ、田、名、在、之、

V字形に並列之且又端一方之角ノ身乳歯用圓形輪

溝ノ方ニ有之乳歯部ト溝ノ部ト輪廓ニ部ト又其乳歯部ト溝ノ部ト

狀乳歯トシテ且角ノ部トシテ又其乳歯部ト溝ノ部ト又其乳歯部ト溝ノ部ト

乳歯部ト溝ノ部ト又其乳歯部ト溝ノ部ト又其乳歯部ト溝ノ部ト

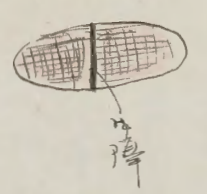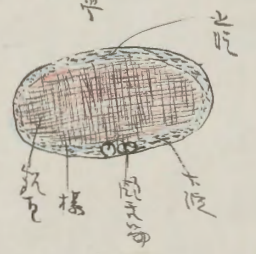

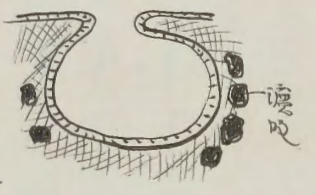
Geschichte Knochens 其構造トシテ又其乳歯部ト溝ノ部ト

乳歯部ト溝ノ部ト又其乳歯部ト溝ノ部ト又其乳歯部ト溝ノ部ト

乳歯部ト溝ノ部ト又其乳歯部ト溝ノ部ト又其乳歯部ト溝ノ部ト

乳歯部ト溝ノ部ト又其乳歯部ト溝ノ部ト又其乳歯部ト溝ノ部ト

乳歯部ト溝ノ部ト又其乳歯部ト溝ノ部ト又其乳歯部ト溝ノ部ト



Handwritten text describing the components shown in the diagrams.

Handwritten text describing the components shown in the diagrams.

Handwritten text describing the components shown in the diagrams.

Handwritten text describing the components shown in the diagrams.

Handwritten text describing the components shown in the diagrams.

Handwritten text

Handwritten text

Handwritten text

Handwritten text

Handwritten text

Handwritten text

Handwritten text

Handwritten text

Handwritten text

Handwritten text

Handwritten text

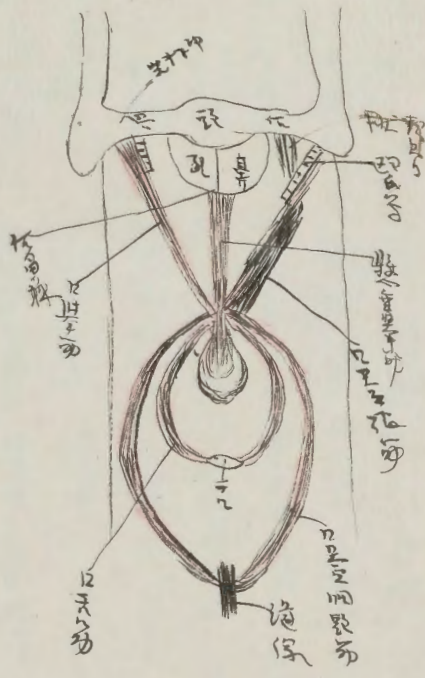
Handwritten text

Handwritten text

Handwritten text



Handwritten notes in Chinese characters, likely describing anatomical details related to the palate and throat.



Palatum durum muscle

Handwritten notes in Chinese characters, possibly describing the function or location of the muscle shown in the diagram.

Handwritten notes in Chinese characters, continuing the anatomical description.

Handwritten notes in Chinese characters, providing further details about the muscles and their actions in the throat region.

Second section header in Chinese characters, likely identifying a specific muscle or anatomical feature.

Handwritten notes in Chinese characters, describing the characteristics and functions of the muscle mentioned in the header.

Section header in Chinese characters, identifying another anatomical structure.

Handwritten notes in Chinese characters, detailing the anatomy and function of the structure.

Section header in Chinese characters, identifying a third anatomical structure.

Handwritten notes in Chinese characters, providing a detailed description of the structure and its role.

Final handwritten notes in Chinese characters, concluding the anatomical discussion on this page.



咽頭筋 (Pharyngeus)

咽頭筋 (Pharyngeus) m. glosso-pharyngeus

咽頭筋 (Pharyngeus) m. glosso-pharyngeus  
咽頭筋 (Pharyngeus) m. glosso-pharyngeus  
咽頭筋 (Pharyngeus) m. glosso-pharyngeus  
咽頭筋 (Pharyngeus) m. glosso-pharyngeus

咽頭筋 (Pharyngeus) m. constrictor pharyngis medius

咽頭筋 (Pharyngeus) m. chondro-pharyngeus

咽頭筋 (Pharyngeus) m. laryngo-pharyngeus

咽頭筋 (Pharyngeus) m. constrictor pharyngis inferior

咽頭筋 (Pharyngeus) m. constrictor pharyngis inferior  
咽頭筋 (Pharyngeus) m. constrictor pharyngis inferior  
咽頭筋 (Pharyngeus) m. constrictor pharyngis inferior

咽頭筋 (Pharyngeus) m. ciliar pharyngeus

咽頭筋 (Pharyngeus) m. thyreo-pharyngeus

咽頭筋 (Pharyngeus) m. levator pharyngis tuberculus  
咽頭筋 (Pharyngeus) m. levator pharyngis tuberculus  
咽頭筋 (Pharyngeus) m. levator pharyngis tuberculus

咽頭筋 (Pharyngeus) m. laryngo-pharyngeus  
咽頭筋 (Pharyngeus) m. laryngo-pharyngeus  
咽頭筋 (Pharyngeus) m. laryngo-pharyngeus

咽頭筋 (Pharyngeus) m. laryngo-pharyngeus  
咽頭筋 (Pharyngeus) m. laryngo-pharyngeus  
咽頭筋 (Pharyngeus) m. laryngo-pharyngeus

軟腭

軟腭筋 (Palatopharyngeus) 咽頭筋 (Pharyngeus)  
軟腭筋 (Palatopharyngeus) 咽頭筋 (Pharyngeus)  
軟腭筋 (Palatopharyngeus) 咽頭筋 (Pharyngeus)  
軟腭筋 (Palatopharyngeus) 咽頭筋 (Pharyngeus)





解新雙田西日

海

(1) 口腔

(一) 托裏人

(二) 口腔深

(三) 齒牙

(四) 舌

(五) 軟口蓋

(2) 齒牙腔

(3) 咽喉

(4) 會管


(5) 田月


(6) 腸

一十二指腸

三空腸 三迴腸

心 大腸  
ノ 胃腸  
ノ 結腸  
ノ 直腸  
レ 脾  
レ 肝臟  
レ 腹  
レ 喉頭





經七五米川師古教被讀義

召曉論

母張道...

一海女

二草草


三知...

用... 折...

粘。演。膜。

粘。演。膜。... 粘。演。膜。...

1. 2. 3. 4. 5. 6. 7. 8. 9. 10. 11. 12. 13. 14. 15. 16. 17. 18. 19. 20. 21. 22. 23. 24. 25. 26. 27. 28. 29. 30. 31. 32. 33. 34. 35. 36. 37. 38. 39. 40. 41. 42. 43. 44. 45. 46. 47. 48. 49. 50. 51. 52. 53. 54. 55. 56. 57. 58. 59. 60. 61. 62. 63. 64. 65. 66. 67. 68. 69. 70. 71. 72. 73. 74. 75. 76. 77. 78. 79. 80. 81. 82. 83. 84. 85. 86. 87. 88. 89. 90. 91. 92. 93. 94. 95. 96. 97. 98. 99. 100.



1. 2. 3. 4. 5. 6. 7. 8. 9. 10. 11. 12. 13. 14. 15. 16. 17. 18. 19. 20. 21. 22. 23. 24. 25. 26. 27. 28. 29. 30. 31. 32. 33. 34. 35. 36. 37. 38. 39. 40. 41. 42. 43. 44. 45. 46. 47. 48. 49. 50. 51. 52. 53. 54. 55. 56. 57. 58. 59. 60. 61. 62. 63. 64. 65. 66. 67. 68. 69. 70. 71. 72. 73. 74. 75. 76. 77. 78. 79. 80. 81. 82. 83. 84. 85. 86. 87. 88. 89. 90. 91. 92. 93. 94. 95. 96. 97. 98. 99. 100.

1. 2. 3. 4. 5. 6. 7. 8. 9. 10. 11. 12. 13. 14. 15. 16. 17. 18. 19. 20. 21. 22. 23. 24. 25. 26. 27. 28. 29. 30. 31. 32. 33. 34. 35. 36. 37. 38. 39. 40. 41. 42. 43. 44. 45. 46. 47. 48. 49. 50. 51. 52. 53. 54. 55. 56. 57. 58. 59. 60. 61. 62. 63. 64. 65. 66. 67. 68. 69. 70. 71. 72. 73. 74. 75. 76. 77. 78. 79. 80. 81. 82. 83. 84. 85. 86. 87. 88. 89. 90. 91. 92. 93. 94. 95. 96. 97. 98. 99. 100.

1. 2. 3. 4. 5. 6. 7. 8. 9. 10. 11. 12. 13. 14. 15. 16. 17. 18. 19. 20. 21. 22. 23. 24. 25. 26. 27. 28. 29. 30. 31. 32. 33. 34. 35. 36. 37. 38. 39. 40. 41. 42. 43. 44. 45. 46. 47. 48. 49. 50. 51. 52. 53. 54. 55. 56. 57. 58. 59. 60. 61. 62. 63. 64. 65. 66. 67. 68. 69. 70. 71. 72. 73. 74. 75. 76. 77. 78. 79. 80. 81. 82. 83. 84. 85. 86. 87. 88. 89. 90. 91. 92. 93. 94. 95. 96. 97. 98. 99. 100.

1. 2. 3. 4. 5. 6. 7. 8. 9. 10. 11. 12. 13. 14. 15. 16. 17. 18. 19. 20. 21. 22. 23. 24. 25. 26. 27. 28. 29. 30. 31. 32. 33. 34. 35. 36. 37. 38. 39. 40. 41. 42. 43. 44. 45. 46. 47. 48. 49. 50. 51. 52. 53. 54. 55. 56. 57. 58. 59. 60. 61. 62. 63. 64. 65. 66. 67. 68. 69. 70. 71. 72. 73. 74. 75. 76. 77. 78. 79. 80. 81. 82. 83. 84. 85. 86. 87. 88. 89. 90. 91. 92. 93. 94. 95. 96. 97. 98. 99. 100.

Handwritten text in vertical columns, likely a list of items or descriptions. The text is written in a cursive script, possibly a form of Arabic or Persian.

積累

所用

部位

口

Handwritten text line

Handwritten text line

Handwritten text line

Handwritten text line

Handwritten text line

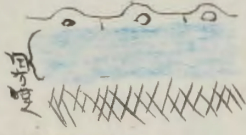
Handwritten text line

Handwritten text line

Handwritten text line

Handwritten text line

Handwritten text in vertical columns on the right page, continuing the list or descriptions.



Handwritten text in vertical columns at the bottom of the right page.



1. 2. 3. 4. 5. 6. 7. 8. 9. 10. 11. 12. 13. 14. 15. 16. 17. 18. 19. 20. 21. 22. 23. 24. 25. 26. 27. 28. 29. 30. 31. 32. 33. 34. 35. 36. 37. 38. 39. 40. 41. 42. 43. 44. 45. 46. 47. 48. 49. 50. 51. 52. 53. 54. 55. 56. 57. 58. 59. 60. 61. 62. 63. 64. 65. 66. 67. 68. 69. 70. 71. 72. 73. 74. 75. 76. 77. 78. 79. 80. 81. 82. 83. 84. 85. 86. 87. 88. 89. 90. 91. 92. 93. 94. 95. 96. 97. 98. 99. 100.

且書世書... 且書世書... 且書世書...

(123456789)



1. 2. 3. 4. 5. 6. 7. 8. 9. 10. 11. 12. 13. 14. 15. 16. 17. 18. 19. 20. 21. 22. 23. 24. 25. 26. 27. 28. 29. 30. 31. 32. 33. 34. 35. 36. 37. 38. 39. 40. 41. 42. 43. 44. 45. 46. 47. 48. 49. 50. 51. 52. 53. 54. 55. 56. 57. 58. 59. 60. 61. 62. 63. 64. 65. 66. 67. 68. 69. 70. 71. 72. 73. 74. 75. 76. 77. 78. 79. 80. 81. 82. 83. 84. 85. 86. 87. 88. 89. 90. 91. 92. 93. 94. 95. 96. 97. 98. 99. 100.

(123456789)

指

Handwritten text in vertical columns, likely a list or index of items.

第



Handwritten text in vertical columns, continuing the list or index.

Small red characters or a stamp at the bottom of the page.

Handwritten text in vertical columns, continuing the list or index.

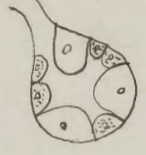Handwritten text in vertical columns, continuing the list or index.

Handwritten text in vertical columns, continuing the list or index.

Handwritten text in Arabic script, likely a preface or introductory section.

Handwritten text in Arabic script, possibly a section header or a specific heading.

Main body of handwritten text in Arabic script, consisting of several lines of dense writing.



Handwritten text in red ink, likely a marginal note or a specific annotation.

Handwritten text in red ink, possibly a section header or a specific heading.

Main body of handwritten text in Arabic script on the right page, continuing the content from the left page.

Handwritten text in red ink, likely a marginal note or a specific annotation.

Handwritten text in red ink, possibly a section header or a specific heading.

Handwritten text in Arabic script, likely a list or index of items.

Handwritten header or title in Arabic script.

Handwritten text in Arabic script, continuing the list or index.

Handwritten header or title in Arabic script.

Handwritten text in Arabic script, continuing the list or index.

Handwritten text in Arabic script, possibly a list of names or titles.

Handwritten header or title in Arabic script.

Handwritten text in Arabic script, continuing the list or index.

Handwritten header or title in Arabic script.

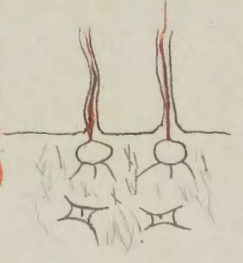Handwritten text in Arabic script, continuing the list or index.





第一時期  
吾人得之於此者，始於上述細胞連續體中之  
一線，此線之存在，乃由細胞之  
分裂而來，其分裂之過程，可  
見於下列之圖中。

細胞分裂



2

細胞分裂之過程，可分為  
四個時期，即：(1) 前期  
(2) 中期 (3) 後期 (4) 末期  
前期：細胞核膜崩解，染色  
體凝縮，紡錘絲開始形成。  
中期：染色體排列於細胞  
赤道板上，紡錘絲與染色  
體之着絲點相連。  
後期：染色體分離，向兩  
極移動。  
末期：染色體到達兩極，  
核膜重新形成，細胞質分  
裂。

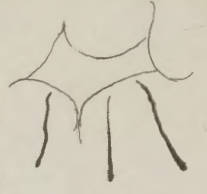細胞分裂

細胞分裂之過程，可分為  
四個時期，即：(1) 前期  
(2) 中期 (3) 後期 (4) 末期

細胞分裂之過程，可分為  
四個時期，即：(1) 前期  
(2) 中期 (3) 後期 (4) 末期  
前期：細胞核膜崩解，染色  
體凝縮，紡錘絲開始形成。  
中期：染色體排列於細胞  
赤道板上，紡錘絲與染色  
體之着絲點相連。  
後期：染色體分離，向兩  
極移動。  
末期：染色體到達兩極，  
核膜重新形成，細胞質分  
裂。

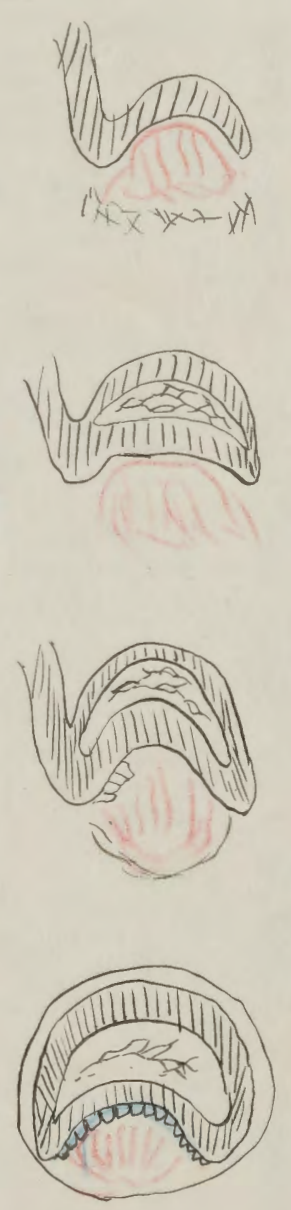
細胞分裂

細胞分裂之過程，可分為  
四個時期，即：(1) 前期  
(2) 中期 (3) 後期 (4) 末期  
前期：細胞核膜崩解，染色  
體凝縮，紡錘絲開始形成。  
中期：染色體排列於細胞  
赤道板上，紡錘絲與染色  
體之着絲點相連。  
後期：染色體分離，向兩  
極移動。  
末期：染色體到達兩極，  
核膜重新形成，細胞質分  
裂。




細胞分裂之過程，可分為  
四個時期，即：(1) 前期  
(2) 中期 (3) 後期 (4) 末期  
前期：細胞核膜崩解，染色  
體凝縮，紡錘絲開始形成。  
中期：染色體排列於細胞  
赤道板上，紡錘絲與染色  
體之着絲點相連。  
後期：染色體分離，向兩  
極移動。  
末期：染色體到達兩極，  
核膜重新形成，細胞質分  
裂。

此種之植物，其葉片之形狀，與普通之植物不同，其葉片之邊緣，有細小之齒狀，且其葉片之基部，有細小之腺體，此種植物，多生長於潮濕之地，其葉片之形狀，與普通之植物不同，其葉片之邊緣，有細小之齒狀，且其葉片之基部，有細小之腺體，此種植物，多生長於潮濕之地。



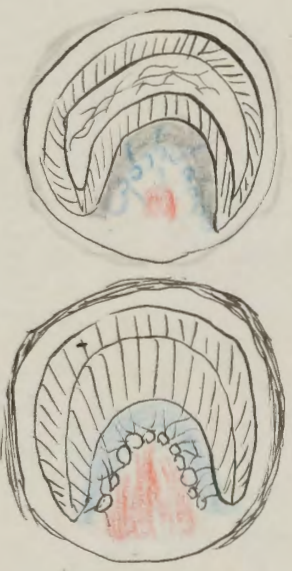
此種植物之葉片，其形狀與普通之植物不同，其葉片之邊緣，有細小之齒狀，且其葉片之基部，有細小之腺體，此種植物，多生長於潮濕之地。

此種植物之葉片，其形狀與普通之植物不同，其葉片之邊緣，有細小之齒狀，且其葉片之基部，有細小之腺體，此種植物，多生長於潮濕之地。





此圖係由一牙醫所繪，其意欲說明牙齒之構造。圖中可見牙齒之冠部、牙根及牙髓腔。圖中文字係德文，其意為：牙齒之構造。圖中可見牙齒之冠部、牙根及牙髓腔。圖中文字係德文，其意為：牙齒之構造。圖中可見牙齒之冠部、牙根及牙髓腔。圖中文字係德文，其意為：牙齒之構造。



此圖係由一牙醫所繪，其意欲說明牙齒之構造。圖中可見牙齒之冠部、牙根及牙髓腔。圖中文字係德文，其意為：牙齒之構造。圖中可見牙齒之冠部、牙根及牙髓腔。圖中文字係德文，其意為：牙齒之構造。

此圖係由一牙醫所繪，其意欲說明牙齒之構造。圖中可見牙齒之冠部、牙根及牙髓腔。圖中文字係德文，其意為：牙齒之構造。圖中可見牙齒之冠部、牙根及牙髓腔。圖中文字係德文，其意為：牙齒之構造。

此圖係由一牙醫所繪，其意欲說明牙齒之構造。圖中可見牙齒之冠部、牙根及牙髓腔。圖中文字係德文，其意為：牙齒之構造。圖中可見牙齒之冠部、牙根及牙髓腔。圖中文字係德文，其意為：牙齒之構造。

此圖係由一牙醫所繪，其意欲說明牙齒之構造。圖中可見牙齒之冠部、牙根及牙髓腔。圖中文字係德文，其意為：牙齒之構造。圖中可見牙齒之冠部、牙根及牙髓腔。圖中文字係德文，其意為：牙齒之構造。

第三圖牙狀

此圖係由一牙醫所繪，其意欲說明牙齒之構造。圖中可見牙齒之冠部、牙根及牙髓腔。圖中文字係德文，其意為：牙齒之構造。圖中可見牙齒之冠部、牙根及牙髓腔。圖中文字係德文，其意為：牙齒之構造。

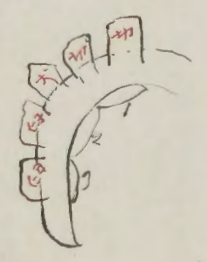
Handwritten text at the top left of the page.

Main handwritten text on the right side of the page, including a signature at the bottom.

Handwritten text on the left side of the page, below the signature.

212 / 212

214 2 / 214 2



Main handwritten text on the right side of the page, including a signature at the bottom.

Handwritten text at the top left of the page.

Main handwritten text on the right side of the page, including a signature at the bottom.

Main handwritten text on the left side of the page, including a signature at the bottom.

Handwritten text at the top left of the page.

五孔道

J C M  
 I I' C M' M"  
 = 2 1 2  
 I C P M  
 I I' C P' M' M' M"  
 7. 9. 11. 10. 11 6 12 18  
 = 2 1 2 3

Handwritten notes in Chinese characters, including the characters '五孔道' and '五孔道'.

五孔道 (五孔道)

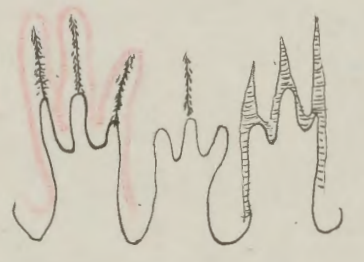
Handwritten notes in Chinese characters, including the characters '五孔道' and '五孔道'.

五孔道

五孔道

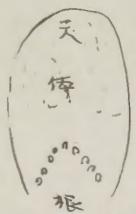五孔道

Handwritten notes in Chinese characters, including the characters '五孔道' and '五孔道'.



Handwritten notes in Chinese characters, including the characters '五孔道' and '五孔道'.

根脈腫



天如地脈

此脈起於左足大指內側，沿足內側上行，入於臍中，上膈，循心，下脊，入於腎，出於右足小指外側，循足外側上行，入於臍中，上膈，循心，下脊，入於腎，出於右足小指外側，循足外側上行，入於臍中，上膈，循心，下脊，入於腎。

第廿九章

此脈起於左足大指內側，沿足內側上行，入於臍中，上膈，循心，下脊，入於腎，出於右足小指外側，循足外側上行，入於臍中，上膈，循心，下脊，入於腎，出於右足小指外側，循足外側上行，入於臍中，上膈，循心，下脊，入於腎。

第卅章

此脈起於左足大指內側，沿足內側上行，入於臍中，上膈，循心，下脊，入於腎，出於右足小指外側，循足外側上行，入於臍中，上膈，循心，下脊，入於腎，出於右足小指外側，循足外側上行，入於臍中，上膈，循心，下脊，入於腎。

正助

正助

此脈起於左足大指內側，沿足內側上行，入於臍中，上膈，循心，下脊，入於腎，出於右足小指外側，循足外側上行，入於臍中，上膈，循心，下脊，入於腎。

此脈起於左足大指內側，沿足內側上行，入於臍中，上膈，循心，下脊，入於腎，出於右足小指外側，循足外側上行，入於臍中，上膈，循心，下脊，入於腎。

此脈起於左足大指內側，沿足內側上行，入於臍中，上膈，循心，下脊，入於腎，出於右足小指外側，循足外側上行，入於臍中，上膈，循心，下脊，入於腎。

此脈起於左足大指內側，沿足內側上行，入於臍中，上膈，循心，下脊，入於腎，出於右足小指外側，循足外側上行，入於臍中，上膈，循心，下脊，入於腎。

正助

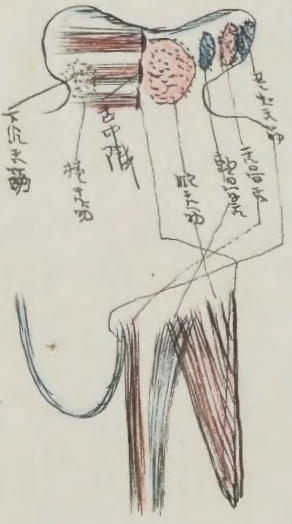
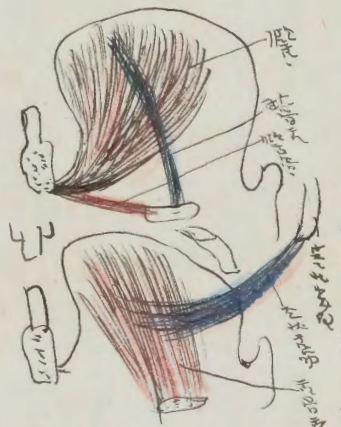此脈起於左足大指內側，沿足內側上行，入於臍中，上膈，循心，下脊，入於腎，出於右足小指外側，循足外側上行，入於臍中，上膈，循心，下脊，入於腎。

正助

此脈起於左足大指內側，沿足內側上行，入於臍中，上膈，循心，下脊，入於腎，出於右足小指外側，循足外側上行，入於臍中，上膈，循心，下脊，入於腎。

正助

۱۰۰  
 ۱۰۱  
 ۱۰۲  
 ۱۰۳  
 ۱۰۴  
 ۱۰۵  
 ۱۰۶  
 ۱۰۷  
 ۱۰۸  
 ۱۰۹  
 ۱۱۰



۱۱۱  
 ۱۱۲  
 ۱۱۳  
 ۱۱۴  
 ۱۱۵  
 ۱۱۶  
 ۱۱۷  
 ۱۱۸  
 ۱۱۹  
 ۱۲۰

۱۲۱ *M. Styloglossus*

۱۲۲  
 ۱۲۳  
 ۱۲۴  
 ۱۲۵  
 ۱۲۶  
 ۱۲۷  
 ۱۲۸  
 ۱۲۹  
 ۱۳۰

۱۳۱  
 ۱۳۲  
 ۱۳۳  
 ۱۳۴  
 ۱۳۵  
 ۱۳۶  
 ۱۳۷  
 ۱۳۸  
 ۱۳۹  
 ۱۴۰

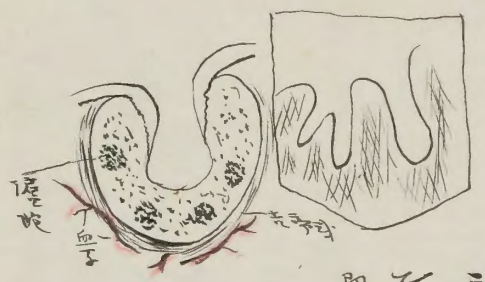
۱۴۱  
 ۱۴۲  
 ۱۴۳  
 ۱۴۴  
 ۱۴۵  
 ۱۴۶  
 ۱۴۷  
 ۱۴۸  
 ۱۴۹  
 ۱۵۰

۱۵۱ *M. Longitudinalis*

۱۵۲  
 ۱۵۳  
 ۱۵۴  
 ۱۵۵  
 ۱۵۶  
 ۱۵۷  
 ۱۵۸  
 ۱۵۹  
 ۱۶۰

۱۶۱

此種之植物，其根生於水底，葉浮於水面，花開於葉腋，果實為球形，內含種子。其葉之形狀，如心臟形，邊緣有波狀之缺刻。其花之顏色，有紅、白、紫等色。其果實之大小，如豌豆。其種子之形狀，如球形。其植物之生長，極其迅速。其葉之壽命，僅數日。其花之壽命，僅數小時。其果實之壽命，僅數日。其種子之壽命，僅數年。



此種之植物，其根生於水底，葉浮於水面，花開於葉腋，果實為球形，內含種子。其葉之形狀，如心臟形，邊緣有波狀之缺刻。其花之顏色，有紅、白、紫等色。其果實之大小，如豌豆。其種子之形狀，如球形。其植物之生長，極其迅速。其葉之壽命，僅數日。其花之壽命，僅數小時。其果實之壽命，僅數日。其種子之壽命，僅數年。

此種之植物，其根生於水底，葉浮於水面，花開於葉腋，果實為球形，內含種子。

此種之植物，其根生於水底，葉浮於水面，花開於葉腋，果實為球形，內含種子。

此種之植物，其根生於水底，葉浮於水面，花開於葉腋，果實為球形，內含種子。

此種之植物，其根生於水底，葉浮於水面，花開於葉腋，果實為球形，內含種子。

Polatum Melaleucum Polatum Melaleucum

此種之植物，其根生於水底，葉浮於水面，花開於葉腋，果實為球形，內含種子。

此種之植物，其根生於水底，葉浮於水面，花開於葉腋，果實為球形，內含種子。

此種之植物，其根生於水底，葉浮於水面，花開於葉腋，果實為球形，內含種子。

此種之植物，其根生於水底，葉浮於水面，花開於葉腋，果實為球形，內含種子。


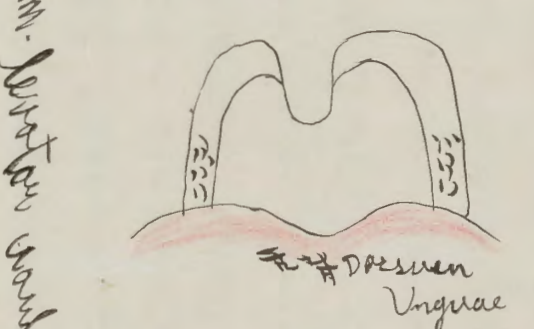
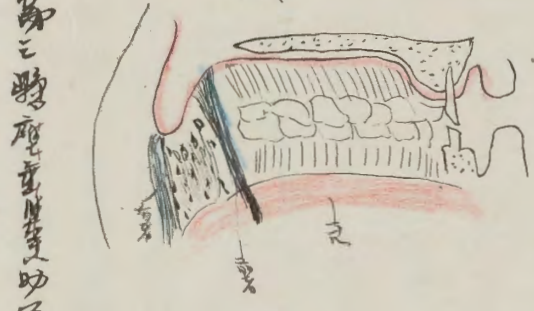
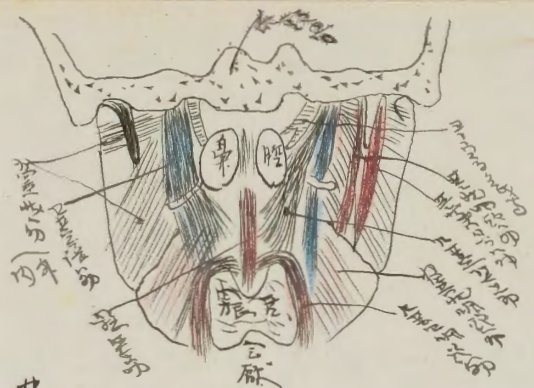
Handwritten Chinese text at the top of the page, including the characters '張' and '動'.

Handwritten Chinese text in the middle section, including characters '收' and '弛'.

Handwritten Chinese text in the lower middle section, including characters '張' and '動'.

Handwritten Chinese text at the bottom of the page, including characters '收' and '弛'.

動張弛



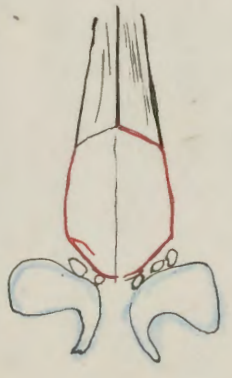
*M. Genioglossus*  
*M. Hyoglossus*  
*M. Styloglossus*  
*M. Lingualis*  
*M. Pharyngeus*

*Dorsum Linguae*  
*M. Tensor Velae Palatinae*  
*M. Palatopharyngeus*  
*M. Palatoglossus*

Handwritten Chinese text at the bottom of the page, including characters '收' and '弛'.

Handwritten text in Chinese characters, likely describing anatomical or medical concepts. The text is arranged in vertical columns.

Handwritten text in Chinese characters, continuing the notes or descriptions.



Handwritten text in Chinese characters, providing further details or instructions related to the anatomical drawing.

Handwritten text in Chinese characters, possibly a title or a specific note.

Handwritten text in Chinese characters, located at the top of the page, possibly a header or a reference.

Handwritten text in Chinese characters, likely a detailed description or a list of items. The text is written in a cursive style.

Handwritten text in Chinese characters, possibly a title or a specific note.

Handwritten text in Chinese characters, including a large, stylized character or symbol that might represent a specific concept or measurement.

Handwritten text in Chinese characters, continuing the notes or descriptions. The text is arranged in vertical columns.

Handwritten text in Chinese characters, possibly a concluding note or a signature.



Handwritten text in a cursive script, likely a historical document or manuscript. The text is written in black ink on aged paper. It begins with a large initial character, possibly '中' (middle), and continues with several lines of dense writing. There are several red markings and characters interspersed throughout the text, including a prominent red character '中' at the top right and another '中' at the bottom right. The script is highly stylized and characteristic of traditional Chinese calligraphy.

Handwritten red text at the top of the page, including the characters '中' and '中'.

Handwritten text in a cursive script, continuing from the previous page. The text is written in black ink on aged paper. It begins with a large initial character, possibly '中' (middle), and continues with several lines of dense writing. There are several red markings and characters interspersed throughout the text, including a prominent red character '中' at the top right and another '中' at the bottom right. The script is highly stylized and characteristic of traditional Chinese calligraphy.

Handwritten red text at the top of the page, including the characters '中' and '中'.

Handwritten text in Arabic script, likely a manuscript or letter. The text is written in black ink on aged paper. There are several lines of text, with some words or phrases underlined in red ink. The script is dense and appears to be a formal or religious document.

Handwritten red text at the top left of the page.

Handwritten red text at the top center of the page.

Handwritten red text at the top right of the page.

Handwritten red text at the top right of the page.

Handwritten red text in the center of the page, possibly a signature or a specific heading.

Handwritten red text at the top right of the page.

Handwritten text in Arabic script, continuing from the previous page. The text is written in black ink on aged paper. There are several lines of text, with some words or phrases underlined in red ink. The script is dense and appears to be a formal or religious document.

Handwritten red text at the top left of the page.

Handwritten red text at the top center of the page.

Handwritten red text at the top right of the page.

Handwritten red text in the center of the page.

Handwritten red text at the top right of the page.

Handwritten red text at the top right of the page.

Handwritten text at the top left of the page, possibly a name or title.

Main body of handwritten text on the right side of the page.

Handwritten red text on the right side of the page.

Handwritten red text on the right side of the page.

Handwritten text on the right side of the page, possibly a signature or date.

Main body of handwritten text on the left side of the page.

Handwritten red text on the left side of the page.

Main body of handwritten text on the left side of the page.

Main body of handwritten text on the left side of the page.

Handwritten red text at the bottom of the page.

Main body of handwritten text at the bottom of the page.

Main body of handwritten text at the bottom of the page.

Main body of handwritten text at the bottom of the page.

Main body of handwritten text at the bottom of the page.

Main body of handwritten text at the bottom of the page.

Main body of handwritten text at the bottom of the page.

Main body of handwritten text at the bottom of the page.

Handwritten red text at the bottom of the page.

Main body of handwritten text at the bottom of the page.

Main body of handwritten text at the bottom of the page.

Main body of handwritten text at the bottom of the page.

Main body of handwritten text at the bottom of the page.

Main body of handwritten text at the bottom of the page.

Handwritten text in vertical columns, likely describing anatomical structures or symptoms.

咽喉狀腺

Handwritten characters below the section header.

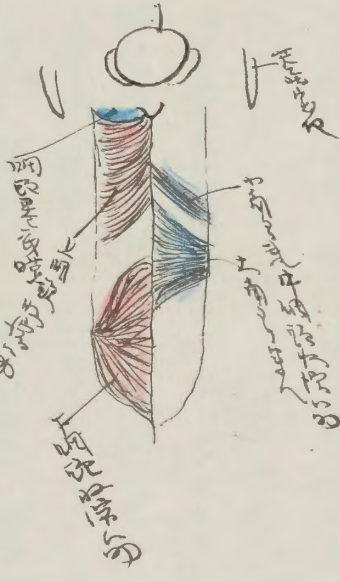
Handwritten text in vertical columns, continuing the anatomical or medical notes.

Handwritten text in vertical columns, possibly a list or classification.

Handwritten text in vertical columns, possibly a list or classification.

Handwritten text in vertical columns, possibly a list or classification.

Handwritten text in vertical columns, possibly a list or classification.



Vertical handwritten text on the right side of the page, likely a legend or additional notes for the diagram.

Handwritten text in vertical columns, likely describing anatomical structures or symptoms.

Handwritten section header in vertical text.

Handwritten characters below the section header.

Handwritten text in vertical columns, continuing the anatomical or medical notes.

Handwritten text in vertical columns, continuing the anatomical or medical notes.

Handwritten text in vertical columns, possibly a list or classification.

Handwritten text in vertical columns, possibly a list or classification.

Handwritten text in vertical columns, possibly a list or classification.

Handwritten text in vertical columns, possibly a list or classification.

Handwritten text in vertical columns, continuing the anatomical or medical notes.

Handwritten text in vertical columns, possibly a list or classification.

Handwritten text in vertical columns, possibly a list or classification.

Handwritten text in vertical columns, possibly a list or classification.

Handwritten text in vertical columns, continuing the anatomical or medical notes.

Handwritten section header in vertical text.

Handwritten section header in vertical text.

Handwritten text in Arabic script, starting with 'بسم الله الرحمن الرحيم' (In the name of Allah, the Most Gracious, the Most Merciful). The text appears to be a religious or philosophical treatise.

Handwritten marginal notes in Arabic script, located on the left side of the page.

Handwritten text in Arabic script, continuing the main text from the previous section.

Handwritten marginal notes in Arabic script, located on the left side of the page.

Handwritten text in Arabic script, continuing the main text. The text is dense and covers most of the page.

Handwritten marginal notes in Arabic script, located on the left side of the page.

Handwritten marginal notes in Arabic script, located on the left side of the page.

Handwritten text in Arabic script, starting with 'بسم الله الرحمن الرحيم' (In the name of Allah, the Most Gracious, the Most Merciful).

Handwritten marginal notes in Arabic script, located on the left side of the page.

Handwritten text in Arabic script, continuing the main text. The text is dense and covers most of the page.

Handwritten marginal notes in Arabic script, located on the left side of the page.

Handwritten text in Arabic script, continuing the main text. The text is dense and covers most of the page.

Handwritten marginal notes in Arabic script, located on the left side of the page.

Handwritten marginal notes in Arabic script, located on the left side of the page.



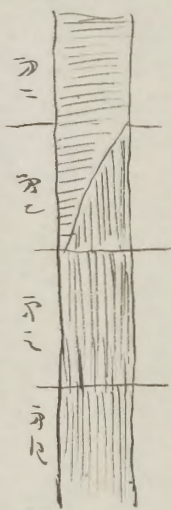
Handwritten text in Arabic script, continuing the main text. The text is dense and covers most of the page.

Handwritten marginal notes in Arabic script, located on the left side of the page.

用藥

用藥

用藥



用藥

用藥

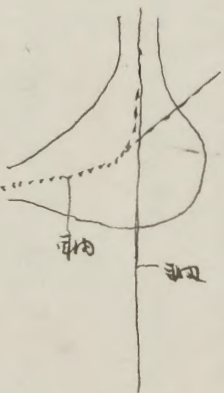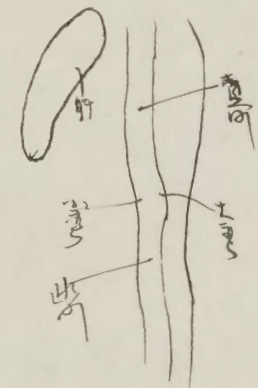
用藥

用藥

用藥

用藥

用藥



用藥

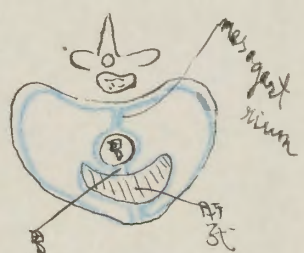
用藥

用藥

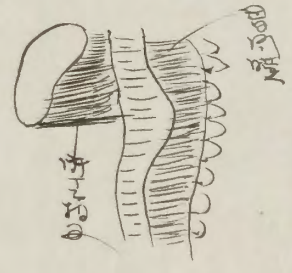
用藥

腸胃消化膜

消化管の構造と機能に関する記述。消化管の各部の位置と役割を説明している。



胃の構造と機能に関する注釈。胃の各部の位置と役割を説明している。



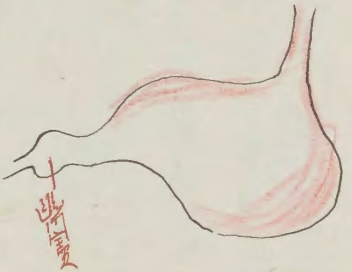
胃の消化機能に関する詳細な記述。胃酸の分泌と消化作用のメカニズムについて説明している。

胃腸界

胃腸の境界線に関する説明。胃と腸の接続部分の構造について述べている。

胃腸の構造に関する注釈。胃腸の各部の位置と役割を説明している。

胃腸の消化機能に関する詳細な記述。腸の蠕動運動と栄養吸収のメカニズムについて説明している。



消化液膜

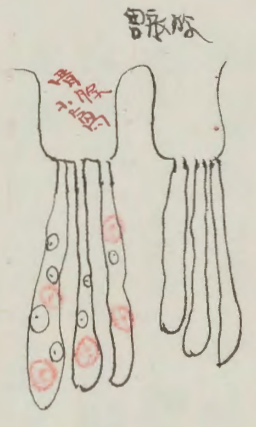
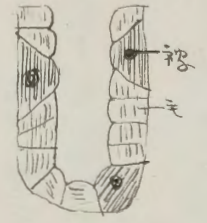
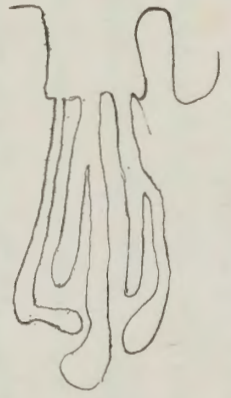
消化液の分泌と作用に関する説明。唾液、胃液、胆汁の役割について述べている。

消化管

消化管の全体的な構造と機能に関する概論。消化管の各部の位置と役割を説明している。

1. 胃腸の消化作用  
 2. 胃腸の蠕動作用  
 3. 胃腸の分泌作用  
 4. 胃腸の吸収作用  
 5. 胃腸の排泄作用

胃腸の消化作用



胃腸の消化作用

胃腸の消化作用  
 胃腸の蠕動作用  
 胃腸の分泌作用  
 胃腸の吸収作用  
 胃腸の排泄作用

胃腸

胃腸

胃腸の消化作用  
 胃腸の蠕動作用  
 胃腸の分泌作用  
 胃腸の吸収作用  
 胃腸の排泄作用

胃腸

胃腸

胃腸の消化作用  
 胃腸の蠕動作用  
 胃腸の分泌作用  
 胃腸の吸収作用  
 胃腸の排泄作用

胃腸



Handwritten text in a cursive script, likely a list or notes. Includes a red heading at the top right.

Handwritten red text at the top right of the page.

Handwritten text in a cursive script, possibly a sub-section or continuation.

Small handwritten red mark or character.

Main body of handwritten text in a cursive script, continuing the list or notes.

Handwritten red text at the top center of the page.

Small handwritten red mark or character.

Small handwritten red mark or character.

Handwritten text in a cursive script, possibly a sub-section or continuation.

Handwritten red text at the top right of the page.

Main body of handwritten text in a cursive script, continuing the list or notes.

Small handwritten red mark or character.

Small handwritten red mark or character.

Main body of handwritten text in a cursive script, continuing the list or notes.

Small handwritten red mark or character.

Main body of handwritten text in a cursive script, continuing the list or notes.

Handwritten red text at the top right of the page.

Handwritten red text at the top right of the page.

Handwritten text in Arabic script, starting with a large initial letter. The text is written in a cursive style.

林版腰

Handwritten text in Arabic script, possibly a title or section header.

Handwritten text in Arabic script, continuing the main body of the text.

Handwritten text in Arabic script, possibly a marginal note.

Handwritten text in Arabic script, continuing the main body of the text.

Handwritten text in Arabic script, possibly a marginal note.

Handwritten text in Arabic script, continuing the main body of the text.

Handwritten text in Arabic script, possibly a marginal note.

Handwritten text in Arabic script, possibly a section header.

Handwritten text in Arabic script, continuing the main body of the text.

Handwritten notes in Arabic script, likely describing a procedure or condition.



Handwritten text in red ink, possibly a title or section header.

Handwritten text in Arabic script, possibly a list or index.

Handwritten text in Arabic script, continuing the notes.

Handwritten text in Arabic script, possibly a detailed description.

Handwritten text in red ink, possibly a title or section header.

Handwritten text in Arabic script, continuing the notes.

Handwritten text in Arabic script, possibly a list or index.

Handwritten text in Arabic script, continuing the notes.

Handwritten text in Arabic script, continuing the notes.


Handwritten text in Arabic script, continuing the notes.

Handwritten text in Arabic script, continuing the notes.

Handwritten text in Arabic script, continuing the notes.



Handwritten text in red ink, possibly a title or section header.



Handwritten text in red ink, possibly a title or section header.

Handwritten text in Arabic script, continuing the notes.

Handwritten text in Arabic script, possibly a list or index.

Handwritten text in Arabic script, continuing the notes.

Handwritten text in Arabic script, continuing the notes.

Handwritten text in Arabic script, continuing the notes.

Handwritten text in Arabic script, continuing the notes.

Handwritten text in Arabic script, continuing the notes.

Handwritten text in Arabic script, continuing the notes.

Handwritten text in Arabic script, continuing the notes.

Handwritten text in Arabic script, continuing the notes.

Handwritten text in Arabic script, continuing the notes.

Handwritten text in Arabic script, continuing the notes.

Handwritten text in Arabic script, continuing the notes.

Handwritten text in Arabic script, continuing the notes.

Handwritten text in Arabic script, continuing the notes.

Handwritten text in red ink, possibly a title or section header.

Handwritten text in red ink, possibly a title or section header.

Handwritten text in red ink, possibly a title or section header.

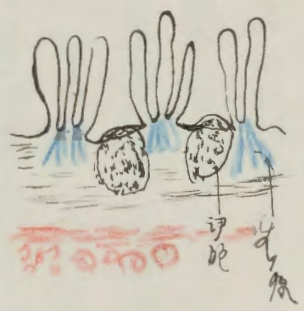
Handwritten text in red ink, possibly a title or section header.

Handwritten text in red ink, possibly a title or section header.

Handwritten text in red ink, possibly a title or section header.

Handwritten text in red ink, possibly a title or section header.


此乃下腹部之主要部分，其位置在骨盆之上方，  
 其形状如梨形，其大小约如成人之拳头，其重量约  
 如成人之拳头，其颜色如肉色，其质地如肌肉，  
 其位置在骨盆之上方，其形状如梨形，其大小约如  
 成人之拳头，其重量约如成人之拳头，其颜色如肉  
 色，其质地如肌肉，其位置在骨盆之上方，其形状  
 如梨形，其大小约如成人之拳头，其重量约如成人  
 之拳头，其颜色如肉色，其质地如肌肉。



十二  
 十二  
 十二

十二

此乃下腹部之主要部分，其位置在骨盆之上方，  
 其形状如梨形，其大小约如成人之拳头，其重量约  
 如成人之拳头，其颜色如肉色，其质地如肌肉，  
 其位置在骨盆之上方，其形状如梨形，其大小约如  
 成人之拳头，其重量约如成人之拳头，其颜色如肉  
 色，其质地如肌肉，其位置在骨盆之上方，其形状  
 如梨形，其大小约如成人之拳头，其重量约如成人  
 之拳头，其颜色如肉色，其质地如肌肉。



细胞  
 细胞核

细胞核 (Nucleus)

Handwritten text in Arabic script, likely a list or index of items.

Handwritten text in Arabic script, continuing the list or index.

Handwritten text in Arabic script, possibly a title or section header.

Handwritten title in Arabic script.

Handwritten text in Arabic script, possibly a description or entry.

Handwritten marginal note in Arabic script.

Handwritten marginal note in Arabic script.

Handwritten marginal note in Arabic script.

Handwritten marginal notes in Arabic script.

Handwritten marginal note in Arabic script.

Handwritten text in Arabic script, likely a list or index of items.

Handwritten text in Arabic script, continuing the list or index.

Handwritten text in Arabic script, possibly a title or section header.

Handwritten marginal note in Arabic script.

Handwritten marginal notes in Arabic script.

Handwritten text in Arabic script, starting with a red heading. The text is dense and covers most of the page.

Handwritten red heading at the top left.

Handwritten red symbol or character.

Handwritten red symbol or character.

Handwritten red heading at the top center.

Handwritten red symbol or character.

Handwritten red symbol or character.

Handwritten red heading in the middle of the page.

Handwritten text in Arabic script, appearing as a separate section or entry.

Handwritten text in Arabic script, possibly a sub-section or continuation.

Handwritten text in Arabic script, continuing the main body of text.

Handwritten text in Arabic script at the top of the right page.

Handwritten red heading at the top left of the right page.

Handwritten text in Arabic script, possibly a sub-section.

Handwritten text in Arabic script, continuing the main body of text.

Handwritten text in Arabic script, continuing the main body of text.

Handwritten text in Arabic script, continuing the main body of text.

Handwritten red heading at the top center of the right page.

Handwritten text in Arabic script, continuing the main body of text.

Handwritten text in Arabic script, continuing the main body of text.

Handwritten text in Arabic script, continuing the main body of text.

Handwritten text in Arabic script, continuing the main body of text.

Handwritten text in Arabic script, continuing the main body of text.


Handwritten text in Arabic script, continuing the main body of text.

Handwritten text in Arabic script, continuing the main body of text.

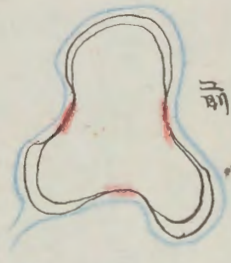
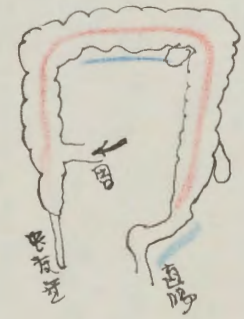
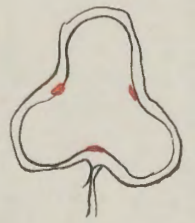
Handwritten text in Arabic script, continuing the main body of text.

Handwritten text in Arabic script, continuing the main body of text.

Handwritten red symbol or character.



第一節 植物の生長と繁殖の過程



植物の生長は、種子の発芽から始まり、根の伸長、葉の展開、花の形成、果実の成熟を経て完了する。この過程は、光、水、養分などの環境要因に大きく影響を受ける。

結腸

動物の消化管は、口から始まり、食道、胃、小腸、大腸を経て肛門に至る。この消化管は、食物を分解し、栄養を吸収する役割を果たしている。

結腸

消化管の構造と機能は、動物の種類によって異なる。例えば、草食動物は長い小腸と大きな盲腸を有し、肉食動物は短い小腸と小さな盲腸を有する。





肝臟

位置

肝臟位於胸腔右側，膈肌之下，橫膈之下，胃之右側。

構造

肝臟由左葉和右葉組成，中間有肝門，肝門內有肝動脈、肝靜脈和膽管。

顏色

肝臟呈紅褐色，表面有黃色的結核。

質地

肝臟質地堅硬，表面有光澤。

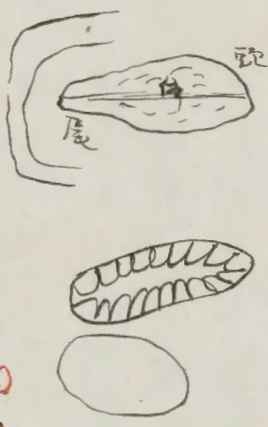
功用

肝臟具有分泌膽汁、儲存糖原、解毒和造血等功能。

疾病

肝臟常見疾病有肝炎、肝硬化、肝癌等。

肝臟在人體中佔有重要地位，是維持生命活動的重要器官。



肝臟

部位  
作用  
顏色

肝臟位於胸腔右側，膈肌之下，橫膈之下，胃之右側。肝臟由左葉和右葉組成，中間有肝門，肝門內有肝動脈、肝靜脈和膽管。肝臟質地堅硬，表面有光澤。肝臟具有分泌膽汁、儲存糖原、解毒和造血等功能。肝臟常見疾病有肝炎、肝硬化、肝癌等。肝臟在人體中佔有重要地位，是維持生命活動的重要器官。

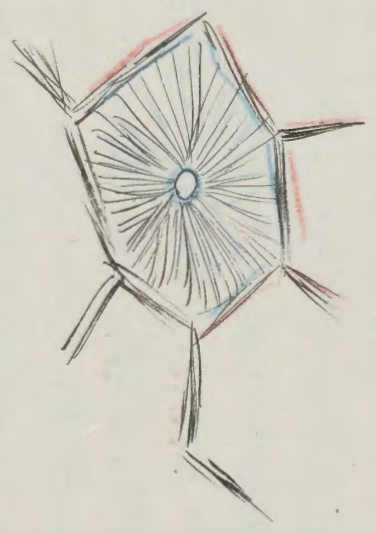
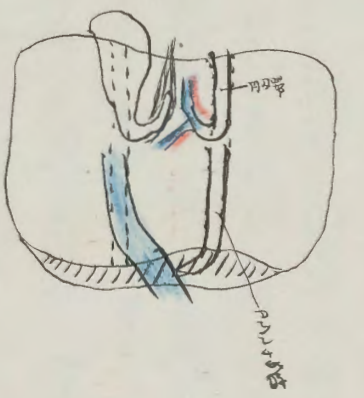
上面

肝臟位於胸腔右側，膈肌之下，橫膈之下，胃之右側。肝臟由左葉和右葉組成，中間有肝門，肝門內有肝動脈、肝靜脈和膽管。肝臟質地堅硬，表面有光澤。肝臟具有分泌膽汁、儲存糖原、解毒和造血等功能。肝臟常見疾病有肝炎、肝硬化、肝癌等。肝臟在人體中佔有重要地位，是維持生命活動的重要器官。

下面  
區別

肝臟與脾臟的區別：肝臟位於胸腔右側，膈肌之下，橫膈之下，胃之右側。脾臟位於胸腔左側，膈肌之下，橫膈之下，胃之左側。肝臟具有分泌膽汁、儲存糖原、解毒和造血等功能。脾臟具有濾血、儲血和免疫功能。肝臟常見疾病有肝炎、肝硬化、肝癌等。脾臟常見疾病有脾腫大、脾破裂等。肝臟在人體中佔有重要地位，是維持生命活動的重要器官。脾臟在人體中佔有重要地位，是維持生命活動的重要器官。

左限畫  
 此種魚類之體形與鱈魚相似，其體形甚扁，且其體色多呈藍色，其體長約一尺，其體寬約二寸，其體厚約一寸，其體形甚扁，且其體色多呈藍色，其體長約一尺，其體寬約二寸，其體厚約一寸。



此種魚類之體形與鱈魚相似，其體形甚扁，且其體色多呈藍色，其體長約一尺，其體寬約二寸，其體厚約一寸，其體形甚扁，且其體色多呈藍色，其體長約一尺，其體寬約二寸，其體厚約一寸。

橫畫

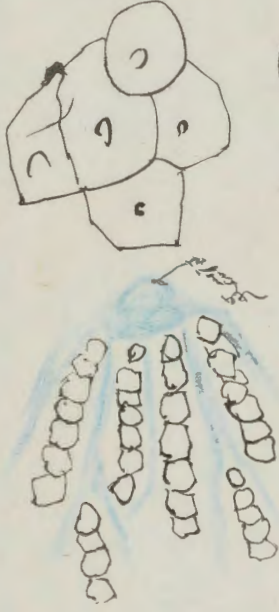此種魚類之體形與鱈魚相似，其體形甚扁，且其體色多呈藍色，其體長約一尺，其體寬約二寸，其體厚約一寸，其體形甚扁，且其體色多呈藍色，其體長約一尺，其體寬約二寸，其體厚約一寸。

橫畫

肝  
 方

此種魚類之體形與鱈魚相似，其體形甚扁，且其體色多呈藍色，其體長約一尺，其體寬約二寸，其體厚約一寸，其體形甚扁，且其體色多呈藍色，其體長約一尺，其體寬約二寸，其體厚約一寸。

Handwritten text in Arabic script, likely a list or index of terms.



Handwritten text in Arabic script, continuing the notes or descriptions.

Handwritten text in red ink, possibly a section header or a specific note.

Handwritten text in Arabic script, continuing the notes or descriptions.

Handwritten text in Arabic script, continuing the notes or descriptions.

Handwritten text in red ink, possibly a section header or a specific note.

Handwritten text in Arabic script, continuing the notes or descriptions.

Handwritten text in red ink, possibly a section header or a specific note.

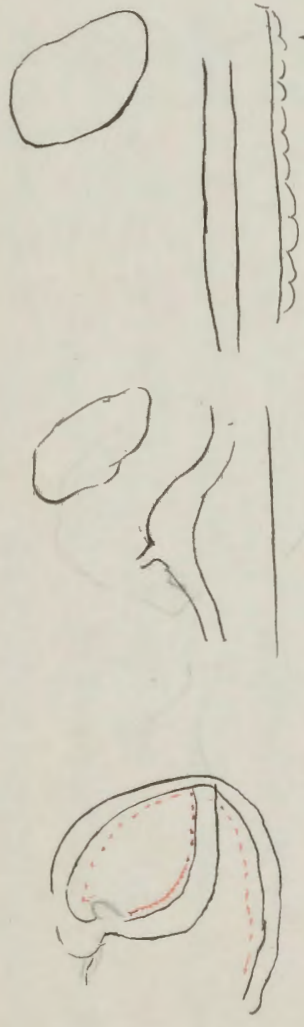
Handwritten text in red ink, possibly a section header or a specific note.

Handwritten text in red ink, possibly a section header or a specific note.

Handwritten text in red ink, possibly a section header or a specific note.





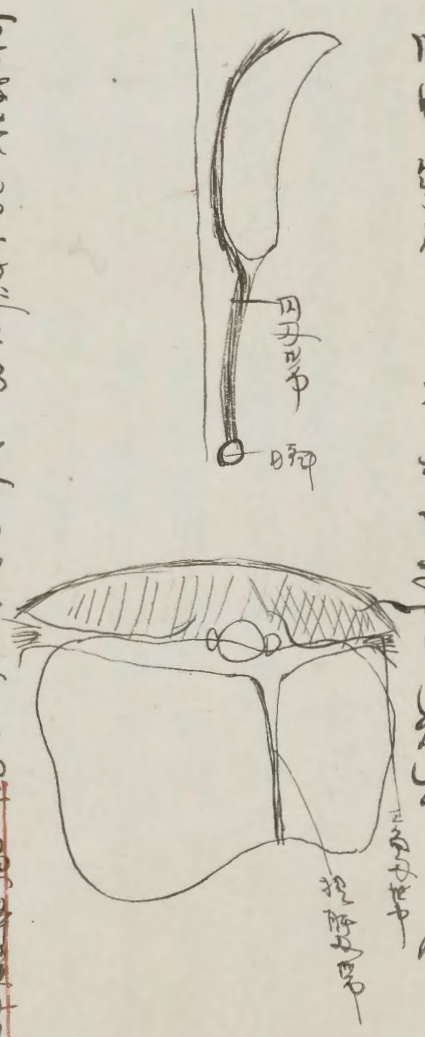


Handwritten text in Chinese characters, written vertically from right to left. The text appears to be a detailed description or classification of the biological structures shown in the sketches. Some characters are underlined in red ink.

Handwritten text in Chinese characters, written vertically from right to left. This section continues the descriptive text from the left page. Some characters are underlined in red ink.

Handwritten text in Chinese characters, positioned between the two main columns of text.

眼  
眼  
Pain to examine



Handwritten text in Chinese characters at the bottom of the right page, likely a title or a reference note.



Handwritten text in vertical columns, likely a list or index. The characters are dense and appear to be a mix of Chinese and possibly other characters. The text is written in a cursive style.

Handwritten text in vertical columns, continuing the list or index. The characters are dense and appear to be a mix of Chinese and possibly other characters. The text is written in a cursive style.



部

Organo variabilis

Handwritten text in a cursive script, likely a list of names or descriptions, including the word 'Organo'.

部

Handwritten text in a cursive script, including the word 'Organo'.

Handwritten text in a cursive script, including the word 'Organo'.

Handwritten text in a cursive script, including the word 'Organo'.

A

Handwritten text in a cursive script, including the word 'Organo'.

Handwritten text in a cursive script, including the word 'Organo'.

Handwritten text in a cursive script, including the word 'Organo'.

Handwritten text in a cursive script, including the word 'Organo'.

Handwritten text in a cursive script, including the word 'Organo'.

Handwritten text in a cursive script, including the word 'Organo'.

Handwritten text in Arabic script, likely a title or introductory passage.

Handwritten text in Arabic script, possibly a section header.

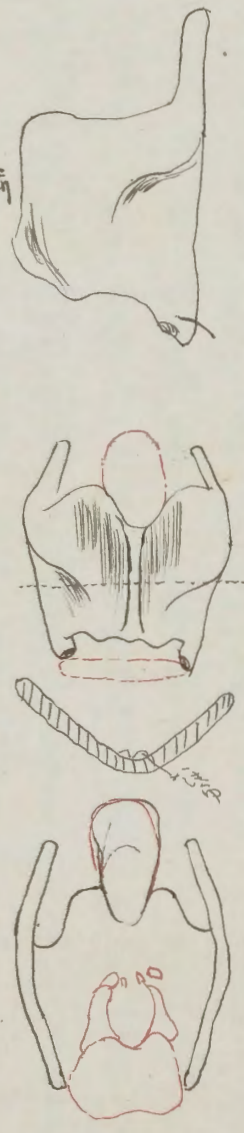
Main body of handwritten text in Arabic script on the left page.

Handwritten section header in Arabic script.

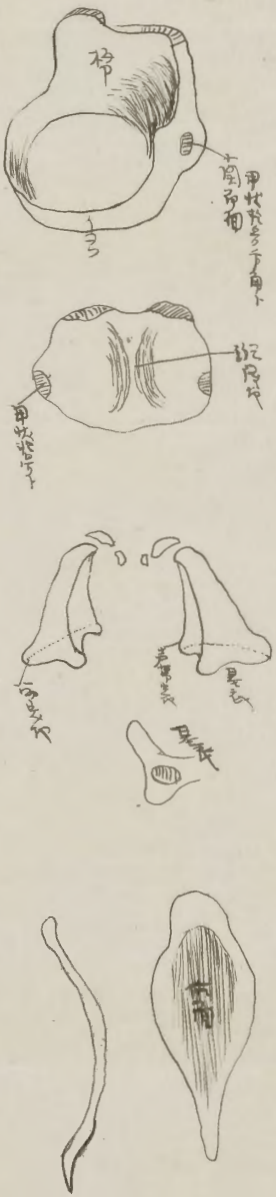Main body of handwritten text in Arabic script on the right page.

Handwritten text in Arabic script at the top of the right page.

Main body of handwritten text in Arabic script on the right page.



Handwritten text in Arabic script at the bottom of the right page.



子宮の構造  
 子宮は卵巣から出る卵を受精させる場所である。子宮の内層は子宮内膜と呼ばれ、受精卵が着床する場所となる。子宮は卵管を通じて卵巣とつながっており、卵管は卵を子宮に運ぶ役割を果たす。

卵巣の構造  
 卵巣は卵を産出する場所である。卵巣は卵管を通じて子宮とつながっており、卵管は卵を子宮に運ぶ役割を果たす。卵巣は卵を産出する場所である。卵巣は卵管を通じて子宮とつながっており、卵管は卵を子宮に運ぶ役割を果たす。

膣の構造  
 膣は卵管を通じて子宮とつながっており、卵管は卵を子宮に運ぶ役割を果たす。膣は卵を産出する場所である。膣は卵管を通じて子宮とつながっており、卵管は卵を子宮に運ぶ役割を果たす。

